

Normobaric hyperoxia improves cerebral blood flow and oxygenation, and inhibits peri-infarct depolarizations in experimental focal ischaemia

Hwa Kyoung Shin,¹ Andrew K. Dunn,² Phillip B. Jones,³ David A. Boas,³ Eng H. Lo,⁴ Michael A. Moskowitz¹ and Cenk Ayata^{1,5}

¹Stroke and Neurovascular Regulation Laboratory, Department of Radiology, Massachusetts General Hospital, Harvard Medical School, Charlestown, MA 02129, ²Biomedical Engineering Department, University of Texas at Austin, Austin, TX 78712, ³Martinos Center for Biomedical Imaging, Department of Radiology, Massachusetts General Hospital, Harvard Medical School, Charlestown, MA 02129, ⁴Neuroprotection Research Laboratory, Department of Radiology, Massachusetts General Hospital, Harvard Medical School, Charlestown, MA 02129 and ⁵Stroke Service and Neuroscience Intensive Care Unit, Department of Neurology, Massachusetts General Hospital, Harvard Medical School, Boston, MA 02114, USA

Correspondence to: Cenk Ayata, Stroke and Neurovascular Regulation Laboratory, Massachusetts General Hospital, 149 13th Street, Room 6403, Charlestown, MA 02129, USA

E-mail: cayata@partners.org

Normobaric hyperoxia is under investigation as a treatment for acute ischaemic stroke. In experimental models, normobaric hyperoxia reduces cerebral ischaemic injury and improves functional outcome. The mechanisms of neuroprotection are still debated because, (i) inhalation of 100% O₂ does not significantly increase total blood O₂ content; (ii) it is not known whether normobaric hyperoxia increases O₂ delivery to the severely ischaemic cortex because of its short diffusion distance; and (iii) hyperoxia may reduce collateral cerebral blood flow (CBF) to ischaemic penumbra because it can cause vasoconstriction. We addressed these issues using real-time two-dimensional multispectral reflectance imaging and laser speckle flowmetry to simultaneously and non-invasively determine the impact of normobaric hyperoxia on CBF and oxygenation in ischaemic cortex. Ischaemia was induced by distal middle cerebral artery occlusion (dMCAO) in normoxic (30% inhaled O₂, arterial pO₂ 134 ± 9 mmHg), or hyperoxic mice (100% inhaled O₂ starting 15 min after dMCAO, arterial pO₂ 312 ± 10 mmHg). Post-ischaemic normobaric hyperoxia caused an immediate and progressive increase in oxyhaemoglobin (oxyHb) concentration, nearly doubling it in ischaemic core within 60 min. In addition, hyperoxia improved CBF so that the area of cortex with ≤20% residual CBF was decreased by 45% 60 min after dMCAO. Furthermore, hyperoxia reduced the frequency of peri-infarct depolarizations (PIDs) by more than 60%, and diminished their deleterious effects on CBF and metabolic load. Consistent with these findings, infarct size was reduced by 45% in the hyperoxia group 2 days after 75 min transient dMCAO. Our data show that normobaric hyperoxia increases tissue O₂ delivery, and that novel mechanisms such as CBF augmentation, and suppression of PIDs may afford neuroprotection during hyperoxia.

Keywords: neuroprotection; laser speckle flowmetry; multispectral reflectance imaging; middle cerebral artery occlusion; acute stroke

Abbreviations: CBF = cerebral blood flow; dMCAO = distal middle cerebral artery occlusion; PID = peri-infarct depolarization

Received October 11, 2006. Revised January 23, 2007. Accepted March 12, 2007. Advance Access publication April 27, 2007

Introduction

Increasing the partial pressure of O₂ in inspired air may be an effective therapeutic option in acute stroke. Earlier studies have focused on hyperbaric hyperoxia; however, its use has been hampered by limited access to a hyperbaric chamber in acute stroke, and potential side effects

(Auer, 2001). Normobaric hyperoxia is an alternative strategy that is generally well-tolerated with fewer potential side effects (e.g. loss of pulmonary surfactant) when administered for <24 h (Matalon *et al.*, 1982; Royston *et al.*, 1990; Carvalho *et al.*, 1998; Brock and Di Giulio, 2006); it is readily available, inexpensive and can be

initiated by emergency medical personnel within minutes after stroke symptom onset. Although normobaric hyperoxia reduced infarct size in all experimental stroke studies (Flynn and Auer, 2002; Singhal *et al.*, 2002a, b; Kim *et al.*, 2005), human experience has been limited. In one study, subjects with severe strokes did not benefit from hyperoxia, and those with mild or moderate stroke had a worse outcome (Ronning and Guldvog, 1999); however, low doses of oxygen were administered (3 l/min via nasal catheter) and the onset of treatment was relatively late (<24 h). The results of a subsequent preliminary human series were promising, where high-flow O₂ therapy was associated with a transient improvement in neurological deficits and lesion volume on diffusion-weighted MRI in select patients with acute ischaemic stroke (Singhal *et al.*, 2005). Reduced morbidity and improved survival was recently reported with 40% O₂ in patients with large MCA strokes (Chiu *et al.*, 2006). However, O₂ therapy in stroke has been criticized citing the risk of enhanced free radical generation, blood–brain barrier breakdown, inflammation and haemorrhage into the infarct. Although some of these concerns have now been allayed (Singhal *et al.*, 2002b; Kim *et al.*, 2005; Liu *et al.*, 2006), two issues remain outstanding. First, increasing the fraction of O₂ in inspired air does not proportionally increase blood O₂ content. This is because under physiological conditions haemoglobin is already saturated by more than 96% when breathing room air, and the direct solubility of O₂ in blood as well as its diffusion distance in brain are limited. Hence, it is not known whether normobaric hyperoxia significantly impacts O₂ delivery to the ischaemic cortex. Secondly, hyperoxia causes vasoconstriction in normal brain (Watson *et al.*, 2000), and thus may impact collateral cerebral blood flow (CBF) supply to ischaemic cortex.

We addressed these questions by measuring changes in haemoglobin oxygenation and CBF in ischaemic cortex through intact skull, using real time simultaneous multispectral reflectance imaging and laser speckle flowmetry (Ruth, 1990; Dunn *et al.*, 2003; Ayata *et al.*, 2004). Our data suggest that normobaric hyperoxia improves both cerebral oxygenation and blood flow, in part by suppressing peri-infarct depolarizations (PIDs).

Material and methods

General surgical preparation

Mice (C57BL/6J, 23–28 g) were housed under diurnal lighting conditions and allowed food and tap water *ad libitum*. Mice were anaesthetized with 2% isoflurane (in 70% N₂O and 30% O₂) and intubated via a tracheostomy. Femoral artery was catheterized for the measurement of blood pressure (BP; ETH 400 transducer amplifier). Anaesthesia was maintained by 1% isoflurane, the depth of anaesthesia was checked by the absence of cardiovascular changes in response to tail pinch. Rectal temperature was kept at 36.8–37.1°C using a thermostatically controlled heating mat (FHC, Brunswick, ME). Mice were paralysed (pancuronium bromide, 0.4 mg/kg/h, i.p.), mechanically ventilated (CWE, SAR-830,

Ardmore, PA) and placed in a stereotaxic frame (David Kopf, Tujunga, CA). Arterial blood gases and pH were measured every 20 min in 25 µl samples (Corning 178 blood gas/pH analyzer, Ciba Corning Diagnostics, Medford, MA). The data were continuously recorded using a data acquisition and analysis system (PowerLab, AD Instruments, Medford, MA) and stored in a computer. Mice were allowed to stabilize for 30 min after surgical preparation.

Focal cerebral ischaemia

Focal cerebral ischaemia was induced by distal middle cerebral artery occlusion (dMCAO). After general surgical preparation, mice were placed in a stereotaxic frame, and skull surface was prepared for optical imaging as described earlier (Ayata *et al.*, 2004; Shin *et al.*, 2006). The temporalis muscle was separated from the temporal bone and removed. A burr hole (2 mm diameter) was drilled under saline cooling in the temporal bone overlying the MCA just above the zygomatic arch. The dura was kept intact and MCA was occluded using a microvascular clip.

Imaging

Multispectral reflectance imaging was performed as described previously in detail (Dunn *et al.*, 2003). Briefly, light from a halogen fibre optic illuminator (Technique R150, Capra Optical, Natick, MA) was passed through six different 10-nm-wide bandpass filters ranging from 560 to 610 nm, placed on a six-position filter wheel (Thorlabs, Newton, NJ), rotating continuously at 3–5 revolutions per second. The filtered light was then coupled into a 12-mm-diameter fibre optic bundle (Edmund Scientific, Tonawanda, NY) for illumination of the cortex. Images were acquired at each illumination band sequentially, captured using a variable magnification objective (×0.75 to ×3, Edmund Optics, Barrington, NJ) and focused either through (infrared laser) or reflected off of (visible light) a dichroic mirror onto two CCD cameras (Coolsnap fx, Roper Scientific 1300 × 1030 pixels, for multispectral; Cohu 4600, San Diego, CA, 640 × 480 pixels, for speckle). The final image size for multispectral imaging was 433 × 343 pixels, after 3 × 3 binning. Raw multispectral data was collected in sequences of 30 frames at 10 Hz (5 frames/wavelength), and a 5 s delay was added to acquire one sequence approximately every 7.5 s. The reflectance image from each wavelength was averaged over the sequence.

Each set of multispectral images was converted to changes in haemoglobin oxygenation and volume using a least squares fitting procedure based on a Monte Carlo model of light propagation in tissue. This approach was used rather than the traditional modified Beer Lambert relationship, which has been shown to be inaccurate for large haemoglobin concentration changes observed during cerebral ischaemia. Briefly, the difference between the intensity changes predicted by the Monte Carlo model for a given set of optical properties (absorption and scattering coefficients) and the measured intensity changes at each time point for all six wavelengths was minimized. The fitting parameters were the absorption and scattering coefficients of the tissue. OxyHb and deoxyHb were assumed to be the only chromophores in the tissue at these wavelengths such that the absorption coefficient was given by:

$$\mu_a(\lambda) = 2.303(\epsilon^{\text{HbO}}(\lambda)C^{\text{HbO}} + \epsilon^{\text{HbR}}(\lambda)C^{\text{HbR}})$$

where ϵ is the molar extinction coefficient and C is the

Table 1 Physiological parameters

	Normoxia (<i>n</i> = 16)		Hyperoxia (<i>n</i> = 18)	
	30% O ₂ (5 min)	30% O ₂ (75 min)	30% O ₂	100% O ₂
pO ₂	148 ± 1	128 ± 2	142 ± 3	336 ± 9
MABP	79 ± 1	70 ± 1	80 ± 2	65 ± 1
pH	7.39 ± 0.01	7.32 ± 0.01	7.40 ± 0.01	7.32 ± 0.01
pCO ₂	36 ± 1	41 ± 2	34 ± 1	41 ± 1

Note: Values are mean ± SEM. MABP (mean arterial blood pressure), pO₂ and pCO₂ are expressed in mmHg. Data from all hyperoxia groups (Experiments I, II and III) were pooled.

concentration of each chromophore. Pre-ischaemic baseline concentrations were assumed to be C_o^{HbO} = 60 μM and C_o^{HbR} = 40 μM.

Laser speckle flowmetry (LSF) was used to study the spatiotemporal characteristics of CBF changes during focal cerebral ischaemia. The technique for LSF has been described in detail elsewhere (Dunn *et al.*, 2001; Ayata *et al.*, 2004). Briefly, a CCD camera (Cohu, San Diego, CA) was positioned above the head, and a laser diode (780 nm) was used to illuminate the intact skull surface in a diffuse manner. The penetration depth of the laser is ~500 μm. Raw speckle images were used to compute speckle contrast, which is a measure of speckle visibility related to the velocity of the scattering particles, and therefore CBF. The speckle contrast is defined as the ratio of the standard deviation of pixel intensities to the mean pixel intensity in a small region of the image (Briers, 2001). Ten consecutive raw speckle images were acquired at 15 Hz (an image set), processed by computing the speckle contrast using a sliding grid of 7 × 7 pixels, and averaged to improve signal-to-noise ratio. Speckle contrast images were converted to images of correlation time values, which represent the decay time of the light intensity autocorrelation function. The correlation time is inversely and linearly proportional to the mean blood velocity (Briers, 2001). Relative CBF images (percentage of baseline) were calculated by computing the ratio of a baseline image of correlation time values to subsequent images. Laser speckle perfusion images were obtained every 7.5 s. Multispectral reflectance and laser speckle images were co-registered using visible surface landmarks, to ensure complete spatial overlap of regions of interest for analysis.

Image analysis

Images were analysed using three different methods (Ayata *et al.*, 2004) to assess the impact of hyperoxia spatiotemporally:

- (1) Based on the severity of CBF reduction during the first minute of dMCAO, three cortical regions of interest (ROIs, 250 × 250 μm) were manually selected corresponding to core (centre of severe CBF reduction), haemodynamic penumbra (steep portion of CBF gradient between core and non-ischaemic cortex) and non-ischaemic cortex. Haemoglobin oxygenation and CBF changes within these ROIs were recorded over time expressed as % of pre-ischaemic baseline.
- (2) Ischaemic CBF deficit was analysed two-dimensionally over time by quantifying the area of cortex (mm²) with either severe (0–20% residual CBF, representing core) or moderate

CBF reduction (21–30% representing penumbra) using a thresholding paradigm.

- (3) In order to determine the gradient of CBF reduction between non-ischaemic cortex and core, we quantified the CBF (% of baseline) along a profile drawn between lambda (0 mm) and the centre of severely ischaemic core.

Peri-infarct depolarizations (PIDs) were identified by observing the attendant spreading CBF and oxygenation changes, which have been previously shown by us and others to reliably detect PIDs in focal ischaemia (Shin *et al.*, 2006; Strong *et al.*, 2006). The impact of PIDs on CBF deficit was two-dimensionally determined by calculating the change in area of severely hypoperfused cortex from 1–5 min before a PID (Pre₁) to 5–10 min after that PID (Post₁), and comparing this change to that from Post₁ to 1–5 min before the next PID (Pre₂). This was then repeated for each subsequent PID, and the average change from Pre to Post (i.e. change with an interval PID) was statistically compared to the average change from Post to Pre (i.e. change without an interval PID), as previously described in detail (Shin *et al.*, 2006).

Experimental protocol

Multimodal imaging of CBF and oxygenation was started 5 min prior to dMCAO and continued uninterrupted for 60 min after the onset or discontinuation of normobaric hyperoxia (75–105 min). The normoxia group was maintained on 30% oxygen, whereas in hyperoxia groups, the fraction of oxygen in inspired air was increased to 100% at 15 (Experiment I) or 45 min after dMCAO (Experiment II). In a third group, normobaric hyperoxia was instituted 15 min after dMCAO and discontinued at 45 min (Experiment III). Mean arterial blood pressure, pH and pCO₂ were monitored and maintained within normal limits in all groups (Table 1).

Infarct volume

The impact of hyperoxia on infarct volume was determined in a separate group of mice without intubation or mechanical ventilation, since these surgical procedures significantly increased morbidity and mortality during the recovery period. To determine infarct volume, microvascular clip was carefully removed after 75 min of dMCAO, and successful reperfusion confirmed using LSF; animals without reperfusion or with haemorrhage during clip removal were excluded from the study. As in the imaging protocol above, normoxic mice (*n* = 6) received 30% O₂ throughout 75 min of ischaemia, whereas hyperoxic mice (*n* = 5) received 100% O₂ starting 15 min after dMCAO. Following clip removal, both groups were maintained breathing room air. Mice were sacrificed 48 h after ischaemia and whole brains were incubated in TTC for 60 min. After photographing the hemispheric surface for measurements of the surface area of infarct, brains were cut into 1 mm thick coronal sections, and infarct area at each section was measured and integrated along the anteroposterior axis to calculate infarct volume. Because infarcts are relatively small in this dMCAO model compared to filament MCAO (fMCAO), only direct infarct volume was compared between groups.

Data analysis

The data were expressed as mean ± standard error of mean (SEM). Statistical comparisons were done using paired or unpaired Student's *t*-test, Mann–Whitney Rank Sum test and one-way

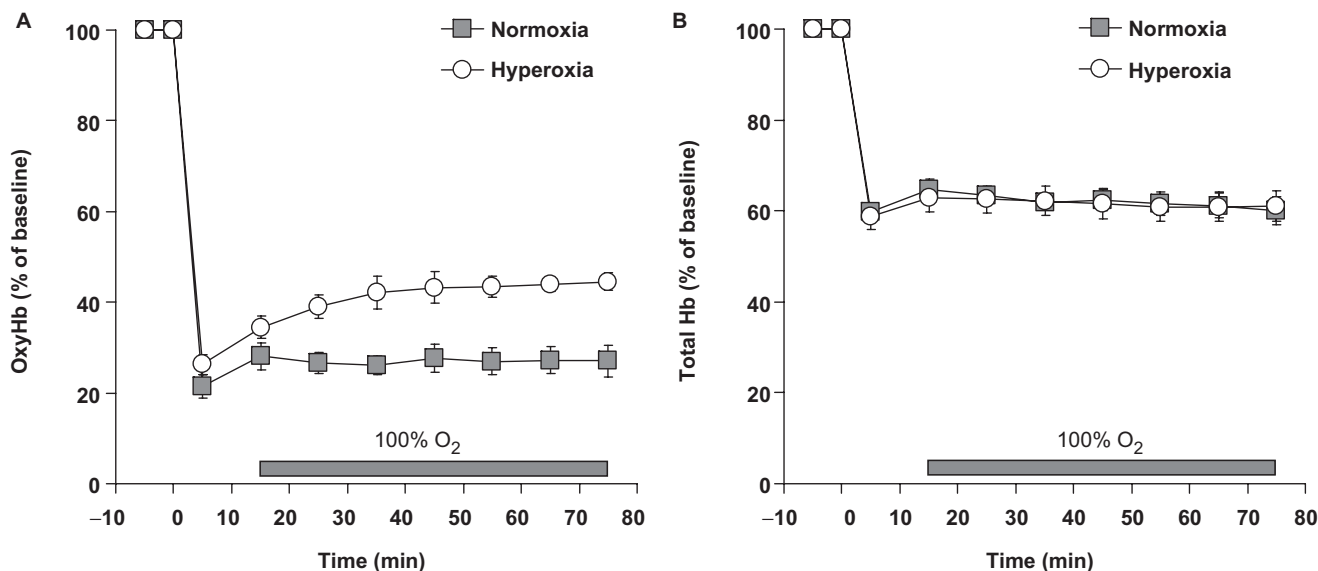


Fig. 1 Hyperoxia increases O₂ delivery in ischaemic core. The time course of changes in core oxyHb (**A**) and total Hb (**B**) concentrations in the normoxia (squares, $n = 11$) and hyperoxia (circles, $n = 8$) groups expressed as % of baseline. Time 0 is the onset of dMCAO. Hyperoxia group inspired 100% O₂ starting from 15 min after dMCAO (horizontal bar, Experiment I). Vertical bars indicate \pm SEM.

ANOVA or two-way ANOVA for repeated measures followed by Fisher's protected least significant difference test, except when otherwise specified. $P < 0.05$ was considered statistically significant.

Results

Cerebral oxygenation

OxyHb and total Hb concentrations abruptly decreased to 20–25 and 60% of baseline in ischaemic core, respectively, immediately after dMCAO, and remained unchanged in normoxic control group throughout the imaging period (Fig. 1). As expected, there was an increase in deoxyHb concentration in both core and penumbra (data not shown). In hyperoxia group, changing the inspired air to 100% O₂ 15 min after dMCAO (Experiment I) increased oxyHb within 10 min, reaching a plateau within 20 min. Sixty minutes after the onset of hyperoxia oxyHb was $\sim 45\%$ of pre-ischaemic baseline, compared to 25% in normoxic group ($P < 0.01$, two-way ANOVA for repeated measures; Fig. 1A). Hyperoxia did not change total Hb concentration in ischaemic core (Fig. 1B), suggesting that the increase in oxyHb during hyperoxia reflects increased O₂ saturation of Hb (Hb_{sat}) rather than increased total Hb concentration. Delayed administration of 100% O₂ 45 min after dMCAO (Experiment II) also increased oxyHb concentration; this effect persisted for at least 60 min (Fig. 3B). Upon discontinuation of 100% O₂ at 45 min (i.e. 30 min after its onset, Experiment III) oxyHb gradually decreased to pre-hyperoxia levels within 60 min (Fig. 3C).

Cerebral blood flow

The area of cortex with severe CBF deficit (i.e. $\leq 20\%$ residual CBF compared to pre-ischaemic baseline) expanded rapidly during the first 10 min of dMCAO, and

did not differ between groups prior to the onset of hyperoxia (15 min; Figs 2 and 3). In normoxic mice, this area continued to expand over the next 60 min, as described previously (Shin *et al.*, 2006). In contrast to normoxic mice, administration of 100% O₂ at 15 min (Experiment I) prevented the expansion of severe CBF deficit over time (2.1 ± 0.4 versus 3.8 ± 0.5 mm², hyperoxia and normoxia, respectively, at 75 min; $P < 0.05$, two-way ANOVA for repeated measures; Fig. 2). Furthermore, delayed administration of hyperoxia 45 min after dMCAO reversed the expansion of severe CBF deficit and restored it to its area at the onset of dMCAO (Experiment II, Fig. 3E). Unlike oxyHb levels, the CBF preserving effect of hyperoxia persisted for at least 60 min after discontinuation of 100% O₂ at 45 min (Experiment III, Fig. 3F). The CBF profile through core, penumbra and non-ischaemic cortex showed that hyperoxia improved CBF in both core and penumbra without significantly impacting non-ischaemic cortex (Fig. 4).

Peri-infarct depolarizations

We have previously shown that PIDs negatively impact CBF in core and penumbra, and their suppression improves perfusion in focal ischaemia (Shin *et al.*, 2006). Therefore, we determined the frequency of PIDs and their impact on CBF and oxygenation, and compared these between normoxia and hyperoxia groups. In normoxic mice, PIDs occurred throughout the recording period (Fig. 5A and C). The frequency of PIDs in hyperoxia groups prior to the onset of 100% O₂ did not differ from normoxic mice (Table 2). Normobaric hyperoxia administered 15 min after dMCAO (Experiment I) abolished PIDs within 15–30 min, and the effect persisted for 60 min (Fig. 5B and D).

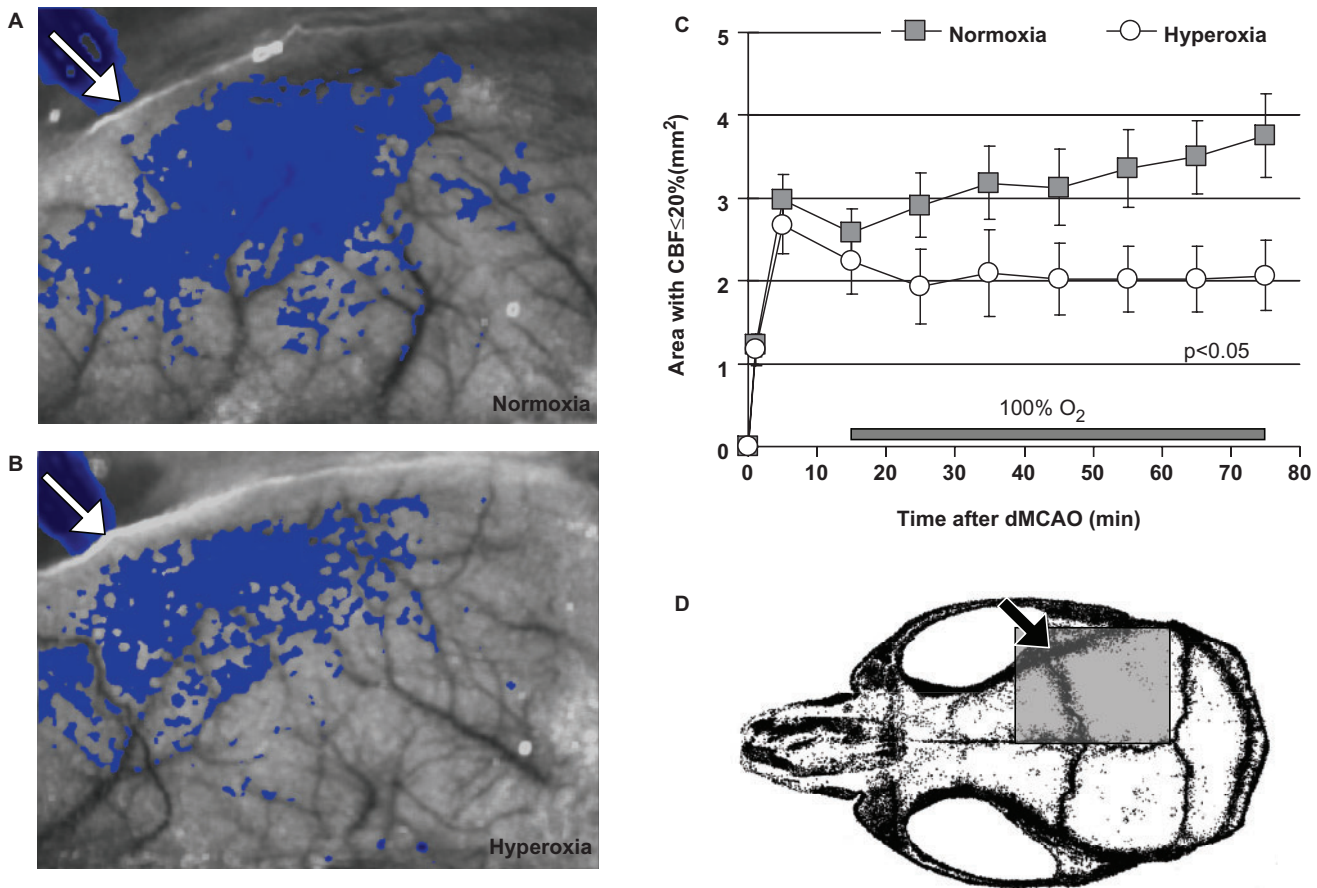


Fig. 2 Hyperoxia preserves CBF after distal middle cerebral artery occlusion. Representative speckle contrast images taken 75 min after dMCAO from normoxia (**A**) and hyperoxia groups (**B**). Superimposed in shades of blue are pixels with residual CBF $\leq 30\%$. The area of cortex with residual CBF $\leq 30\%$ was smaller in hyperoxia group compared to normoxia. (**C**) The time course of changes in area of cortex with severe CBF deficit (residual CBF $\leq 20\%$) in normoxia (squares, $n = 11$) and hyperoxia mice (circles, $n = 8$). Time 0 indicates dMCAO. Horizontal bar represents 100% O₂ starting from 15 min after dMCAO (Experiment I). The area of CBF deficit was quantified using a thresholding paradigm (see 'Methods' section). Vertical error bars indicate \pm SEM. (**D**) Mouse skull showing the position of imaging field (gray rectangle) from which speckle contrast images were acquired over the right hemisphere. Arrows indicate the location of microvascular clip occluding distal MCA.

Delayed administration of 100% O₂ at 45 min (Experiment II) also tended to suppress PIDs (Fig. 5E, Table 2). Upon discontinuing 100% O₂ at 45 min (Experiment III), PIDs recurred within 15–30 min (Fig. 5F, Table 2).

Each PID was associated with a transient hypoperfusion (Shin *et al.*, 2006) accompanied by a reduction in oxyHb in ischaemic core and penumbra (Fig. 6). In normoxic mice, both oxyHb and CBF failed to recover to pre-PID baseline; therefore, each PID caused a stepwise worsening of CBF and oxygenation thus contributing to the expansion of ischaemic cortex over time ($13 \pm 8\%$ increase in the area of severe CBF deficit by each PID, $P < 0.05$). In contrast to normoxia, hyperoxia ameliorated both the magnitude and the duration of transient hypoperfusion and oxyHb reduction during PIDs (Fig. 6). In addition, CBF and oxyHb completely recovered to baseline after a PID in hyperoxic mice. Hence, PIDs did not significantly expand the area of hypoperfused cortex in hyperoxic group ($1 \pm 3\%$ increase in the area of severe CBF deficit by each PID).

Infarct size

Hyperoxia reduced infarct volume by 45% compared to normoxic mice when measured 48 h after 75 min transient dMCAO (Fig. 7). This neuroprotective effect was evident at all anteroposterior slice levels.

Normobaric hyperoxia in normal cortex

In a separate group of non-ischaemic mice ($n = 4$), 15 min of normobaric hyperoxia did not significantly alter oxyHb ($13 \pm 6\%$ increase, $P > 0.05$), and induced a small but statistically significant decrease in CBF ($9 \pm 6\%$, $P < 0.05$, one-way ANOVA for repeated measures).

Discussion

Improving brain tissue oxygenation via 100% O₂ inhalation is a potential therapeutic strategy to save salvageable tissue in acute ischaemic stroke. Here, we provide evidence that normobaric hyperoxia administered 15 min after the onset

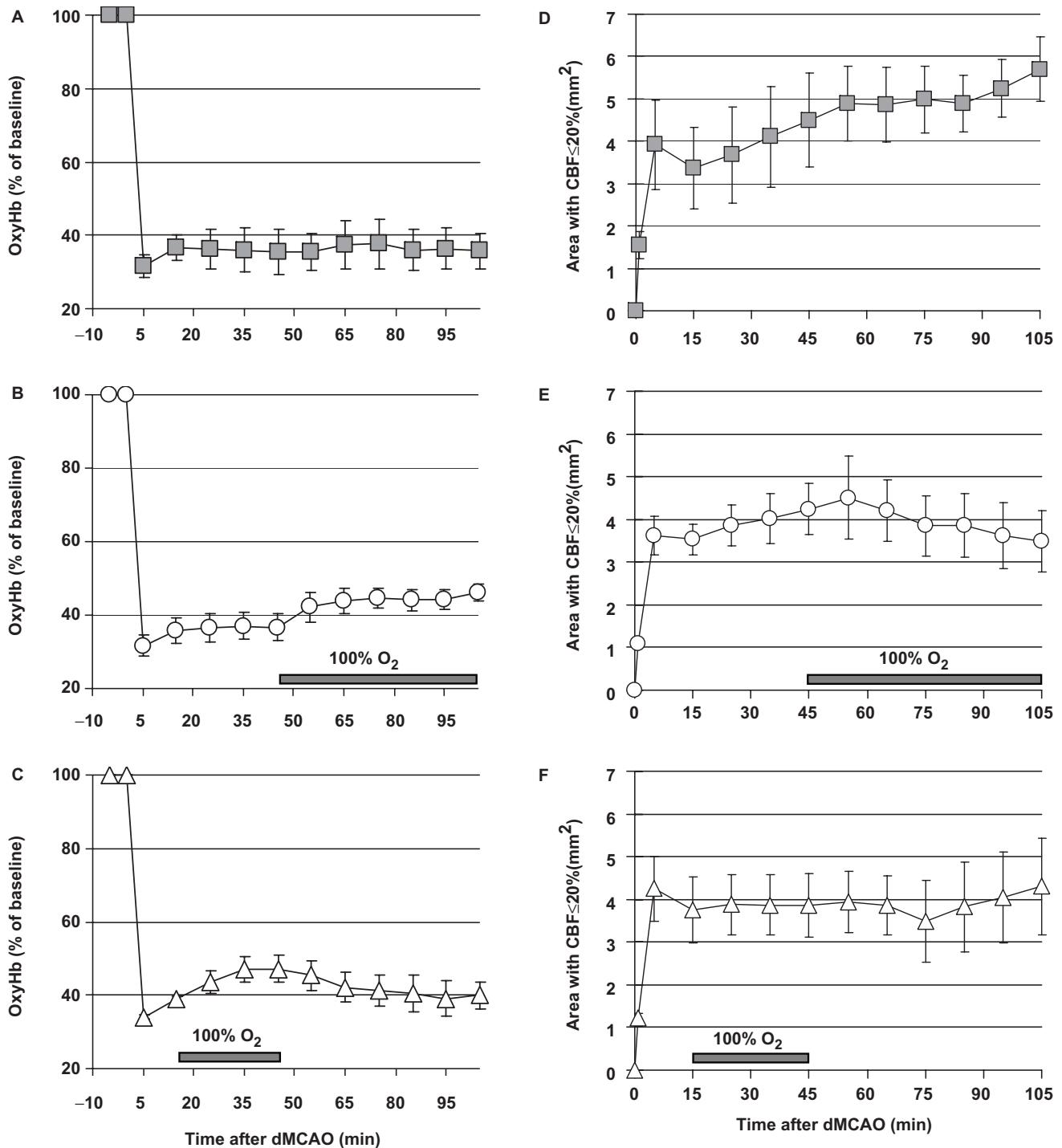


Fig. 3 The effects of delayed administration or early discontinuation of normobaric hyperoxia on CBF and oxygenation. The time courses of changes in core oxyHb concentration and the area of severely ischaemic cortex after dMCAO are shown from Experiments II (B and E, 100% O₂ starting at 45 min after dMCAO; $n = 5$) and III (C and F, 100% O₂ between 15 and 45 min of dMCAO, $n = 5$), along with normoxic time controls (A and D, $n = 5$). Vertical bars indicate \pm SEM.

of focal ischaemia increases oxygen delivery, improves CBF and inhibits PIDs and their deleterious effects on CBF and oxygenation, thereby reducing infarct size. Delayed administration of hyperoxia at 45 min still improved CBF and oxygenation and suppressed PIDs, suggesting that the therapeutic window for these physiological effects is

favourable for clinical use. Furthermore, early discontinuation of hyperoxia was associated with return of oxyHb to pre-hyperoxia levels and recurrence of PIDs, whereas CBF preservation was longer lasting. Our data are consistent with previous studies showing reduction in infarct size after normobaric hyperoxia, and reveal novel mechanisms of

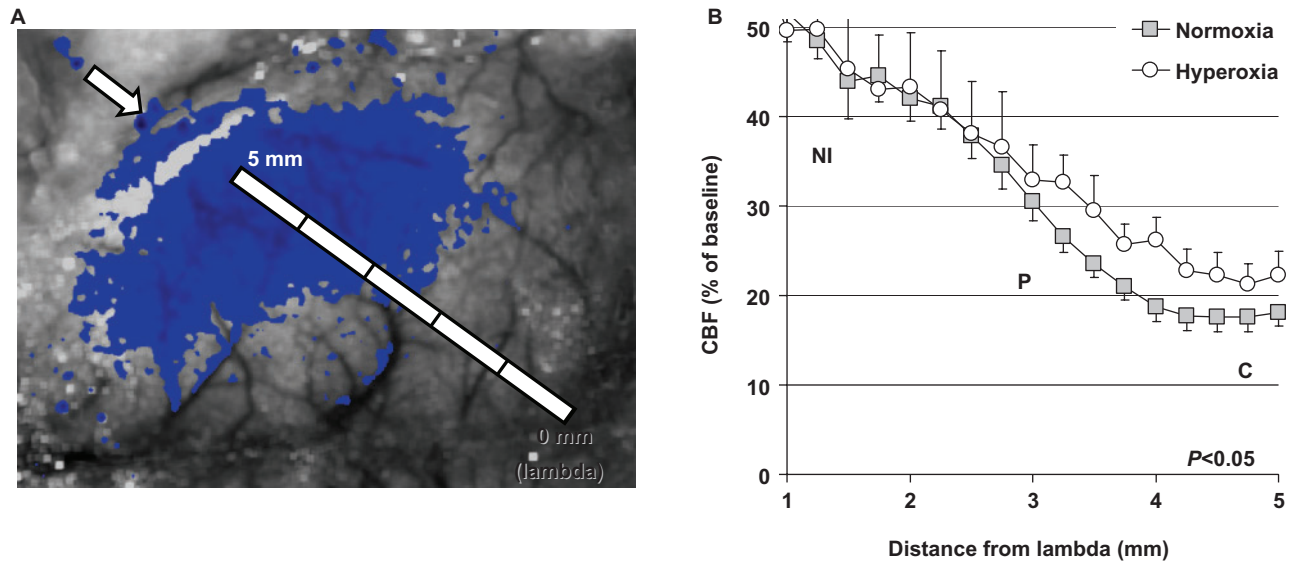


Fig. 4 Hyperoxia preserves CBF in both core and penumbra. **(A)** The CBF profile between non-ischaemic cortex and ischaemic core was determined along a 5 mm line drawn between lambda (0 mm) and the microvascular clip occluding distal MCA (arrow), and plotted as % of baseline CBF and distance from lambda. The bright band at the lateral edge of ischaemic territory is artifact introduced by the insertion of microvascular clip through the temporal bone; such artefacts were manually excluded from the ROI for CBF analysis. **(B)** Normobaric hyperoxia ($n = 8$) increased CBF in both core (**C**, residual CBF $\leq 20\%$) and penumbra (**P**, residual CBF 21–30%) compared to normoxia ($n = 11$), without a significant impact on mildly ischaemic or non-ischaemic cortex (**NI**, residual CBF $> 30\%$). Data are from 75 min after dMCAO. Error bars represent \pm SEM.

hyperoxic neuroprotection in focal ischaemia related to cerebrovascular function and PIDs.

Normobaric hyperoxia is neuroprotective in experimental cerebral ischaemia across a wide range of species including rats, rabbits (Kaminogo, 1989) and baboons (Branston *et al.*, 1976). For example, in rats normobaric hyperoxia reduced diffusion weighted magnetic resonance imaging abnormalities and infarct volumes, improved functional outcome and extended the therapeutic window for thrombolysis, without increasing markers of oxidative stress or blood–brain barrier breakdown (Miyamoto and Auer, 2000; Flynn and Auer, 2002; Singhal *et al.*, 2002a, b; Kim *et al.*, 2005; Liu *et al.*, 2006). The magnitude of reduction in infarct volume by hyperoxia was somewhat smaller in our study; however, differences in ischaemia model (dMCAO versus fMCAO) and duration, duration of hyperoxia, and species preclude a comparison of efficacy of normobaric hyperoxia in this and previous studies. The importance of ischaemia model is highlighted in a recent study where normobaric hyperoxia was beneficial in permanent dMCAO but not fMCAO in mice (Veltkamp *et al.*, 2006). Furthermore, normobaric hyperoxia was less efficacious in permanent ischaemia (Veltkamp *et al.*, 2006) underscoring the importance of achieving reperfusion. Published data also suggest that normobaric hyperoxia has a therapeutic window of < 45 min, at least in rats (Singhal *et al.*, 2002a), although in mouse dMCAO model normobaric hyperoxia was still effective when administered 120 min after ischaemia onset (Veltkamp *et al.*, 2006). We administered hyperoxia 15 or 45 min after ischaemia onset

in order to maximize its potential benefit, and because this is an achievable period of time within which normobaric hyperoxia can be instituted by emergency medical technicians in human hyperacute stroke. Our data suggest a benefit from hyperoxia when administered early after stroke onset (45 min or less), and more work is needed to determine the therapeutic window for normobaric hyperoxia to improve CBF and oxygenation, inhibit PIDs and reduce infarct size.

Tissue pO_2 in normal brain increases in a linear fashion with normobaric hyperoxia (Duong *et al.*, 2001). The presumed mechanism of neuroprotection by normobaric hyperoxia has been increased O_2 delivery to ischaemic neurons and glia thus improving oxidative metabolism. Although our imaging technique does not measure tissue pO_2 directly, we confirmed increased O_2 delivery indirectly by showing a rapid and sustained increase in oxyHb concentration in the severely ischaemic core. Increased tissue pO_2 by normobaric hyperoxia was previously demonstrated by Liu *et al.* (2004, 2006) using electron paramagnetic resonance (EPR) oximetry. However, these investigators observed pO_2 increases only in ischaemic penumbra but not core when measured during 70% O_2 inhalation (Liu *et al.*, 2004); in their subsequent study, where 100% O_2 was tested, core pO_2 was not measured (Liu *et al.*, 2006). In addition to a lower concentration of inhaled O_2 (70 versus 100% in our study), the apparent lack of increase in core pO_2 in their study may be due to: (i) severe ischaemia model yielding greater infarction volumes (filament MCAO) compared to dMCAO used

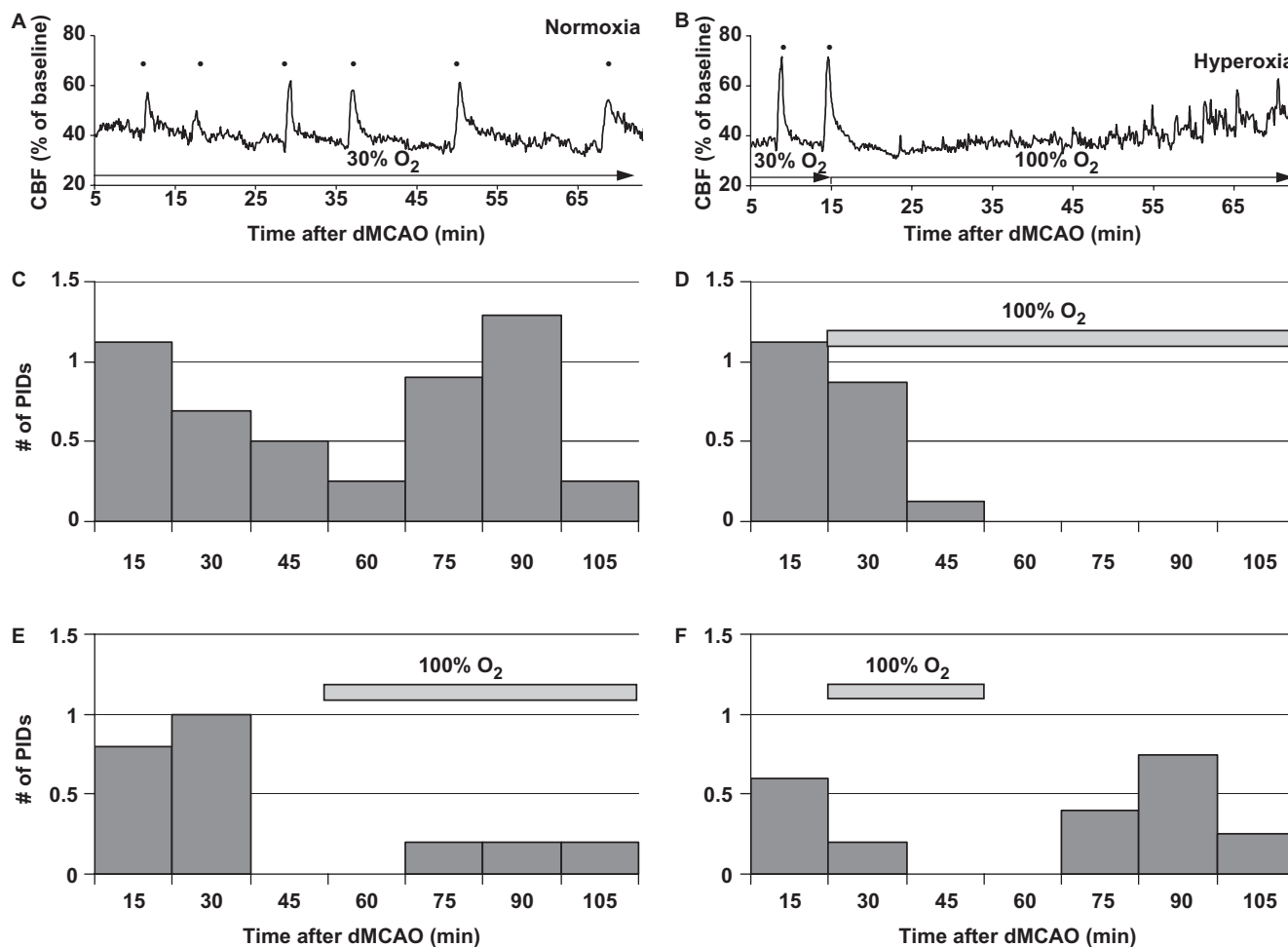


Fig. 5 Hyperoxia suppresses peri-infarct depolarizations. **(A)** Distal MCAO caused repetitive PIDs in normoxic mice, as shown in this representative CBF tracing obtained from mildly ischaemic cortex. In this particular example, six PIDs were observed (black dots). **(B)** The occurrence of PIDs was inhibited after the onset of 100% O₂ inhalation. The PID frequency histogram in normoxic **(C)**, $n = 16$ or hyperoxic mice **(D)**, Experiment I, $n = 8$; **(E)**, Experiment II, $n = 5$; **(F)**, Experiment III, $n = 5$). The frequency of PIDs is expressed as the average number of PIDs occurring during each 15 min period. Horizontal grey bars indicate 100% O₂.

here, (ii) striatal localization of the EPR probe and (iii) local tissue factors due to the invasive nature of EPR oximetry requiring implantation of a lithium phthalocyanine crystal in the region where pO₂ is measured. In this respect, using multimodal imaging we measured oxygenation in cerebral cortex, where the impact of hyperoxia is much stronger compared to striatum (Miyamoto and Auer, 2000; Flynn and Auer, 2002). Furthermore, multimodal imaging through intact skull is non-invasive, better preserving the integrity of the neurovascular unit and cerebrovascular physiology. In support of our data, Kaminogo. (1989) showed that mild hyperoxia (40–50% O₂) increases tissue O₂ availability in focal ischaemic core in rabbits measured using polarography. Although the relatively small size of mouse brain may facilitate the entry of O₂ into ischaemic core, indirect evidence from baboons as well as humans suggest that normobaric hyperoxia augments oxygenation in ischaemic cortex in gyrencephalic brains as well (Branston *et al.*, 1976; Hoffman *et al.*, 1997).

Although hyperoxia causes vasoconstriction in normal brain, this effect is mostly observed during hyperbaric hyperoxia. Studies in different species including humans suggest that normobaric hyperoxia causes only a mild reduction in CBF in normal brain ($\leq 15\%$ of baseline CBF) (Busija *et al.*, 1980; Bergo and Tyssebotn, 1995; Sjoberg *et al.*, 1999; Matsuura *et al.*, 2000; Watson *et al.*, 2000; Duong *et al.*, 2001; Johnston *et al.*, 2003; Bulte *et al.*, 2007). Hence, it has been difficult to predict whether the vasoconstrictive effect of normobaric hyperoxia would impact CBF deficit in focal ischaemia. It has been proposed that hyperoxic vasoconstriction in non-ischaemic cortex may redirect the blood flow to ischaemic territories, thus providing a net benefit. An alternative view is that vasoconstriction in non-ischaemic cortex may increase the vascular resistance in collateral vessels, thereby causing a net reduction in CBF. We directly addressed this question using two-dimensional high spatiotemporal resolution CBF mapping, and showed that normobaric hyperoxia augments

Table 2 Suppression of peri-infarct depolarizations during normobaric hyperoxia

Exp I	Normoxia (n = 16)	30% O ₂ (0–15 min)	30% O ₂ (16–75 min)	
		4.0 [2.0–8.0]	2.0 [1.3–2.5] ^a	
	Hyperoxia (n = 8)	30% O ₂ (0–15 min)	100% O ₂ (16–75 min)	
		4.0 [2.0–8.0]	0.3 [0.0–1.3] ^b	
Exp II	Normoxia (n = 16)	30% O ₂ (0–45 min)	30% O ₂ (46–105 min)	
		2.7 [1.3–4.7]	2.0 [0.5–4.0]	
	Hyperoxia (n = 5)	30% O ₂ (0–45 min)	100% O ₂ (46–105 min)	
		2.7 [2.0–3.0]	1.0 [0.0–1.0] ^c	
Exp III	Normoxia (n = 16)	30% O ₂ (0–15 min)	30% O ₂ (16–45 min)	30% O ₂ (46–105 min)
		4.0 [2.0–8.0]	2.0 [0.5–4.0]	2.0 [0.5–4.0]
	Hyperoxia (n = 5)	30% O ₂ (0–15 min)	100% O ₂ (16–45 min)	30% O ₂ (46–105 min)
		4.0 [3.0–4.0]	0.0 [0.0–0.0] ^d	1.0 [0.8–2.0] ^e

Note: Values are frequency of PIDs (per hour) expressed as median [25–75% range]. Experimental protocols: I, 100% O₂ starting 15 min after dMCAO; II, 100% O₂ starting 45 min after dMCAO; III, 100% O₂ between 15 and 45 min of dMCAO. Numbers in parentheses indicate periods of 30 or 100% O₂ administration within which PID frequencies were calculated. The frequency of PIDs in the single pooled normoxic control group was analysed at the time intervals corresponding to those in Experiments I–III. All normoxia experiments were pooled into a single control group. Mann–Whitney Rank Sum test was used to compare different time intervals within a group, or normoxic control group to hyperoxic groups within a time interval.

^aP = 0.080 versus 30% O₂ (0–15 min).

^bP < 0.05 versus 30% O₂ (16–75 min).

^cP = 0.075 versus 30% O₂ (46–105 min).

^dP < 0.05 versus 30% O₂ (16–45 min).

^eP < 0.05 versus 100% O₂ (16–45 min).

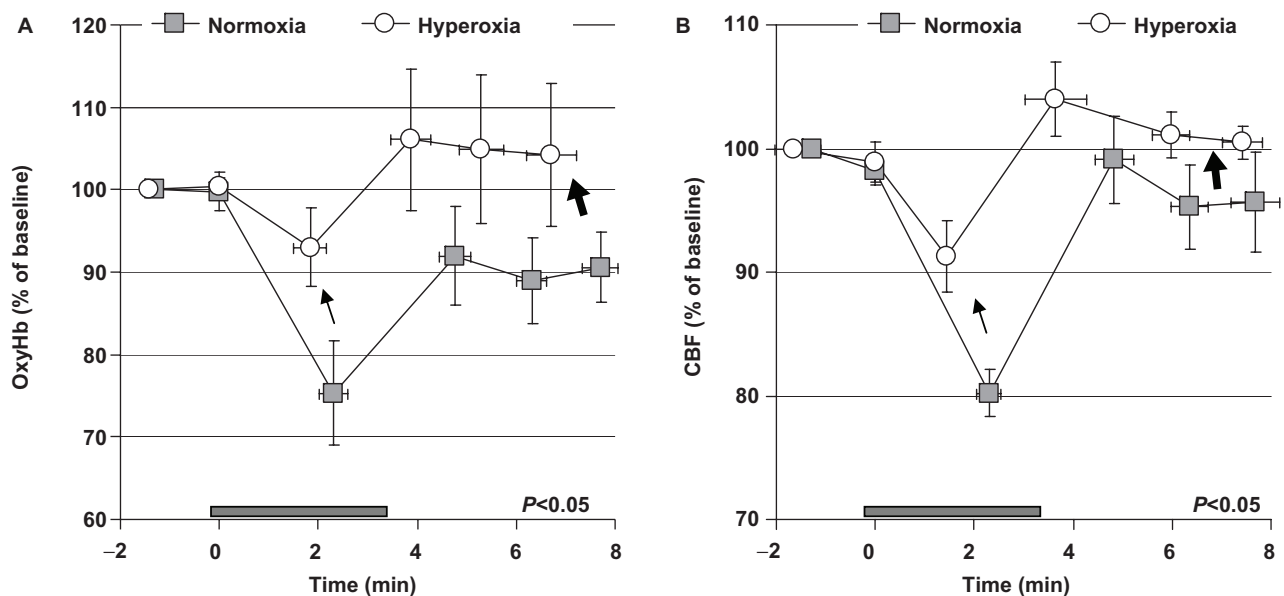


Fig. 6 Hyperoxia attenuates the worsening in oxyHb and CBF during PIDs. The time course of oxyHb (A) and CBF (B) in ischaemic core during PIDs from normoxic (square, n = 11) and hyperoxic (circle, n = 8) mice. The DC potential shift during a PID (approximate timing is shown by the horizontal grey bar) temporally corresponds to the hypoperfusion phase, as shown in detail previously (Shin et al., 2006); therefore, electrophysiological recordings were not undertaken in this study in order preserve cortical physiology. Hyperoxia reduced the transient reduction in oxyHb and CBF during each PID (line arrows), and augmented their recovery after the PID (block arrows). Therefore, hyperoxia ameliorated the negative impact of PIDs on oxyHb and CBF compared to normoxia (two-way ANOVA for repeated measures). The impact of PIDs on CBF and oxygenation was quantified by measuring the magnitude of CBF and oxyHb changes and their latency from the onset of hypoperfusion at the following major deflection points: the onset (time 0) and the trough of abrupt deoxygenation and hypoperfusion, the peak of subsequent increase, return to baseline and 1.5 min after return to baseline. OxyHb and CBF data were expressed as % of baseline 1–2 min before the occurrence of a PID. The time course of oxyHb and CBF changes were then plotted against their latency from the onset of abrupt deoxygenation and hypoperfusion (time 0). Data are the average of all PIDs occurring after 15 min of dMCAO in normoxic and hyperoxic groups from Experiment I. Vertical and horizontal bars indicated the SEM for the magnitude of oxyHb and CBF changes, and their latency, respectively.

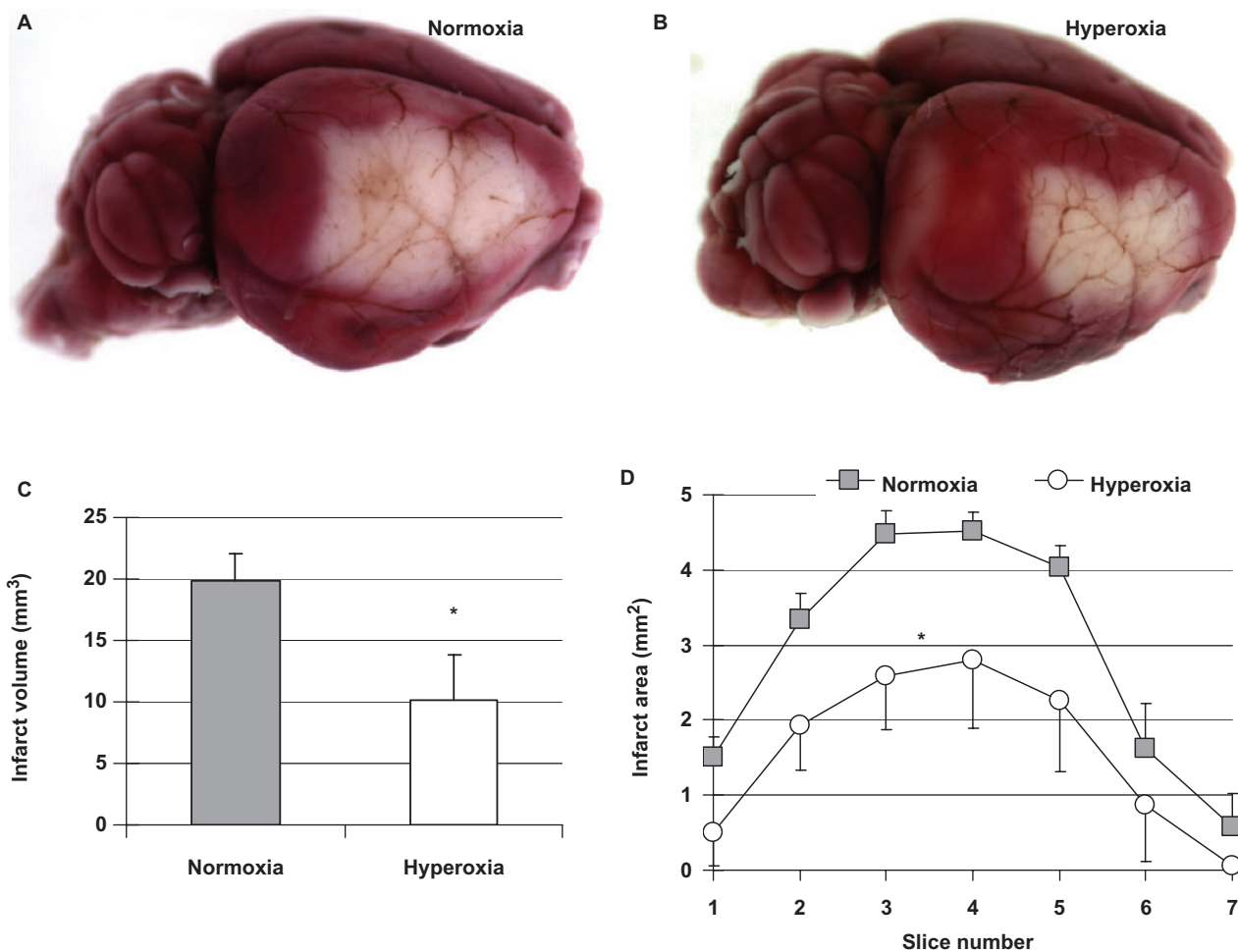


Fig. 7 Normobaric hyperoxia reduces infarct size. **(A)** Topical TTC-stained brain from a representative normoxic mouse showing the dorsolateral cortical infarct 48 h after 75 min transient dMCAO. **(B)** Topical TTC-stained brain from a representative hyperoxic mouse showing the reduction in infarct size. **(C)** Normobaric hyperoxia (white, $n = 5$) starting 15 min after dMCAO reduced infarct volume compared to normoxia (grey, $n = 6$), as calculated by integrating the infarct areas in 1 mm thick coronal sections following topical TTC staining. * $P < 0.05$, t -test. **(D)** The area of infarct in individual 1 mm thick coronal slice levels showing that the neuroprotective effect of hyperoxia (circle) was apparent at all coronal levels compared to normoxia (square). * $P < 0.05$, two-way ANOVA for repeated measures.

CBF in ischaemic penumbra and core without altering CBF in mildly ischaemic or non-ischaemic territories. As a result, the area of severe CBF deficit (i.e. $\leq 20\%$ residual CBF) was reduced by 45% compared to normoxic mice. Our data is in agreement with previous studies in both animals and humans, showing improvement in both CBV and CBF within ischaemic regions during normobaric hyperoxia, in the absence of arterial recanalization (Singhal *et al.*, 2002a, 2005; Liu *et al.*, 2006). Hyperoxic cerebral vasoconstriction is absent or reversed in acutely ischaemic hemisphere (Nakajima *et al.*, 1983).

The mechanism of improved CBF in ischaemic cortex is unclear. Our data do not support shunting of blood from non-ischaemic to ischaemic cortex, because, normobaric hyperoxia did not cause vasoconstriction in non-ischaemic cortex. Other potential mechanisms include improved endothelial nitric oxide synthase (eNOS) function, and

attenuation of vasoconstrictive neurovascular coupling (Shin *et al.*, 2006). It is well-known that NO synthesized by eNOS plays a pivotal role in maintaining CBF in ischaemic cortex. Oxygen is one of the substrates for NO production by eNOS, and may become a rate limiting factor under hypoxic and ischaemic conditions. Therefore, it is possible that hyperoxia augments eNOS activity in ischaemic cortex, thereby increasing CBF; this hypothesis remains to be tested. Alternatively, hyperoxia may attenuate vasoconstrictive coupling, an abnormal neurovascular coupling phenomenon operational under pathological circumstances including artificially elevated extracellular $[K^+]$, inhibition of nitric oxide synthase, subarachnoid haemorrhage and cerebral ischaemia (Dreier *et al.*, 1998, 2000; Strong *et al.*, 2005; Shin *et al.*, 2006). We have recently demonstrated that intense ischaemic depolarizing events, such as anoxic depolarization and PIDs, are

associated with vasoconstriction and worsening in CBF effectively expanding the CBF deficit over time in a stepwise manner (Shin *et al.*, 2006). Here, we show that the stepwise CBF worsening during a PID and the expansion of CBF deficit are abolished by normobaric hyperoxia (Figs 2, 3 and 6). Therefore, our data suggest that the improvement in CBF during hyperoxia is, at least in part, due to attenuation of vasoconstrictive neurovascular coupling during PIDs (Shin *et al.*, 2006), although normobaric hyperoxia administered after reperfusion was still neuroprotective in one study (Flynn and Auer, 2002).

Normobaric hyperoxia also significantly reduced the frequency of PIDs (Fig. 5). The mechanism may involve improved oxygenation and stabilization within ischaemic penumbra. In separate experiments, we determined that normobaric hyperoxia does not inhibit cortical spreading depression in normal cortex (data not shown), suggesting that hyperoxia does not decrease cortical susceptibility to spreading depolarizations such as PIDs. Regardless of its mechanism, inhibition of PIDs is expected to reduce the hemodynamic and metabolic burden on penumbra and thus reduce infarct size. The relevance of suppression of PIDs to human stroke is underscored by recent demonstration of frequent PIDs in human brain after traumatic cerebral injury and subarachnoid haemorrhage (Strong *et al.*, 2005; Fabricius *et al.*, 2006).

In summary, our results show that normobaric hyperoxia increases tissue O₂ availability in focal cerebral ischaemia, and CBF augmentation and suppression of PIDs are two other implicated mechanisms. Our data also suggest that to fully observe hyperoxic neuroprotection, hyperoxia may need to be administered early after ischaemia onset and preferably continued until reperfusion is achieved. In order to minimize pulmonary toxicity, however, normobaric hyperoxia should be considered a transitional tool (24 h or less) to synergize with more conventional therapies aimed to achieve reperfusion. As such, stroke subtypes and the therapeutic window within which normobaric hyperoxia is efficacious, and the optimal duration of administration beyond which it may potentially become harmful remain to be determined in acute stroke.

Acknowledgements

This work was supported by the American Heart Association (0335519N, CA) and National Institutes of Health (P50 NS10828 and PO1 NS35611, MAM K25NS041291, AKD; R01EB00790-01A2, DAB; R01-NS37074 and R01-NS56458, EHL). Funding to pay the Open Access publication charges for this article was provided by American Heart Association SDG0335519N.

References

Auer RN. Non-pharmacologic (physiologic) neuroprotection in the treatment of brain ischemia. *Ann N Y Acad Sci* 2001; 939: 271–82.
Ayata C, Dunn AK, Gursoy OY, Huang Z, Boas DA, Moskowitz MA. Laser speckle flowmetry for the study of cerebrovascular physiology in normal

and ischemic mouse cortex. *J Cereb Blood Flow Metab* 2004; 24: 744–55.
Bergo GW, Tyssebotn I. Effect of exposure to oxygen at 101 and 150 kPa on the cerebral circulation and oxygen supply in conscious rats. *Eur J Appl Physiol Occup Physiol* 1995; 71: 475–84.
Branston NM, Symon L, Crockard HA. Recovery of the cortical evoked response following temporary middle cerebral artery occlusion in baboons: relation to local blood flow and PO₂. *Stroke* 1976; 7: 151–7.
Briers JD. Laser Doppler, speckle and related techniques for blood perfusion mapping and imaging. *Physiol Meas* 2001; 22: R35–66.
Brock TG, Di Giulio C. Prolonged exposure to hyperoxia increases perivascular mast cells in rat lungs. *J Histochem Cytochem* 2006; 54: 1239–46.
Bulte DP, Chiarelli PA, Wise RG, Jezzard P. Cerebral perfusion response to hyperoxia. *J Cereb Blood Flow Metab* 2007; 27: 69–75.
Busija DW, Orr JA, Rankin JH, Liang HK, Wagerle LC. Cerebral blood flow during normocapnic hyperoxia in the unanesthetized pony. *J Appl Physiol* 1980; 48: 10–5.
Carvalho CR, de Paula Pinto Schettino G, Maranhao B, Bethlem EP. Hyperoxia and lung disease. *Curr Opin Pulm Med* 1998; 4: 300–4.
Chiu EH, Liu CS, Tan TY, Chang KC. Venturi mask adjuvant oxygen therapy in severe acute ischemic stroke. *Arch Neurol* 2006; 63: 741–4.
Dreier JP, Ebert N, Priller J, Megow D, Lindauer U, Klee R, et al. Products of hemolysis in the subarachnoid space inducing spreading ischemia in the cortex and focal necrosis in rats: a model for delayed ischemic neurological deficits after subarachnoid hemorrhage? *J Neurosurg* 2000; 93: 658–66.
Dreier JP, Korner K, Ebert N, Gorner A, Rubin I, Back T, et al. Nitric oxide scavenging by hemoglobin or nitric oxide synthase inhibition by N-nitro-L-arginine induces cortical spreading ischemia when K⁺ is increased in the subarachnoid space. *J Cereb Blood Flow Metab* 1998; 18: 978–90.
Dunn AK, Bolay H, Moskowitz MA, Boas DA. Dynamic imaging of cerebral blood flow using laser speckle. *J Cereb Blood Flow Metab* 2001; 21: 195–201.
Dunn AK, Devor A, Bolay H, Andermann ML, Moskowitz MA, Dale AM, et al. Simultaneous imaging of total cerebral hemoglobin concentration, oxygenation, and blood flow during functional activation. *Opt Lett* 2003; 28: 28–30.
Duong TQ, Iadecola C, Kim SG. Effect of hyperoxia, hypercapnia, and hypoxia on cerebral interstitial oxygen tension and cerebral blood flow. *Magn Reson Med* 2001; 45: 61–70.
Fabricius M, Fuhr S, Bhatia R, Boutelle M, Hashemi P, Strong AJ, et al. Cortical spreading depression and peri-infarct depolarization in acutely injured human cerebral cortex. *Brain* 2006; 129: 778–90.
Flynn EP, Auer RN. Eubaric hyperoxemia and experimental cerebral infarction. *Ann Neurol* 2002; 52: 566–72.
Hoffman WE, Charbel FT, Edelman G, Ausman JI. Brain tissue oxygenation in patients with cerebral occlusive disease and arteriovenous malformations. *Br J Anaesth* 1997; 78: 169–71.
Johnston AJ, Steiner LA, Balestreri M, Gupta AK, Menon DK. Hyperoxia and the cerebral hemodynamic responses to moderate hyperventilation. *Acta Anaesthesiol Scand* 2003; 47: 391–6.
Kaminogo M. The effects of mild hyperoxia and/or hypertension on oxygen availability and oxidative metabolism in acute focal ischaemia. *Neurol Res* 1989; 11: 145–9.
Kim HY, Singhal AB, Lo EH. Normobaric hyperoxia extends the reperfusion window in focal cerebral ischemia. *Ann Neurol* 2005; 57: 571–5.
Liu S, Liu W, Ding W, Miyake M, Rosenberg GA, Liu KJ. Electron paramagnetic resonance-guided normobaric hyperoxia treatment protects the brain by maintaining penumbral oxygenation in a rat model of transient focal cerebral ischemia. *J Cereb Blood Flow Metab* 2006; 26: 1274–84.

- Liu S, Shi H, Liu W, Furuichi T, Timmins GS, Liu KJ. Interstitial pO₂ in ischemic penumbra and core are differentially affected following transient focal cerebral ischemia in rats. *J Cereb Blood Flow Metab* 2004; 24: 343–9.
- Matalon S, Nesarajah MS, Farhi LE. Pulmonary and circulatory changes in conscious sheep exposed to 100% O₂ at 1 ATA. *J Appl Physiol* 1982; 53: 110–6.
- Matsuura T, Fujita H, Kashikura K, Kanno I. Modulation of evoked cerebral blood flow under excessive blood supply and hyperoxic conditions. *Jpn J Physiol* 2000; 50: 115–23.
- Miyamoto O, Auer RN. Hypoxia, hyperoxia, ischemia, and brain necrosis. *Neurology* 2000; 54: 362–71.
- Nakajima S, Meyer JS, Amano T, Shaw T, Okabe T, Mortel KF. Cerebral vasomotor responsiveness during 100% oxygen inhalation in cerebral ischemia. *Arch Neurol* 1983; 40: 271–6.
- Ronning OM, Guldvog B. Should stroke victims routinely receive supplemental oxygen? A quasi-randomized controlled trial. *Stroke* 1999; 30: 2033–7.
- Royston BD, Webster NR, Nunn JF. Time course of changes in lung permeability and edema in the rat exposed to 100% oxygen. *J Appl Physiol* 1990; 69: 1532–7.
- Ruth B. Blood flow determination by the laser speckle method. *Int J Microcirc Clin Exp* 1990; 9: 21–45.
- Shin HK, Dunn AK, Jones PB, Boas DA, Moskowitz MA, Ayata C. Vasoconstrictive neurovascular coupling during focal ischemic depolarizations. *J Cereb Blood Flow Metab* 2006; 26: 1018–30.
- Singhal AB, Benner T, Roccatagliata L, Koroshetz WJ, Schaefer PW, Lo EH, et al. A pilot study of normobaric oxygen therapy in acute ischemic stroke. *Stroke* 2005; 36: 797–802.
- Singhal AB, Dijkhuizen RM, Rosen BR, Lo EH. Normobaric hyperoxia reduces MRI diffusion abnormalities and infarct size in experimental stroke. *Neurology* 2002a; 58: 945–52.
- Singhal AB, Wang X, Sumii T, Mori T, Lo EH. Effects of normobaric hyperoxia in a rat model of focal cerebral ischemia-reperfusion. *J Cereb Blood Flow Metab* 2002b; 22: 861–8.
- Sjoberg F, Gustafsson U, Eintrei C. Specific blood flow reducing effects of hyperoxaemia on high flow capillaries in the pig brain. *Acta Physiol Scand* 1999; 165: 33–8.
- Strong AJ, Bezzina EL, Anderson PJ, Boutelle MG, Hopwood SE, Dunn AK. Evaluation of laser speckle flowmetry for imaging cortical perfusion in experimental stroke studies: quantitation of perfusion and detection of peri-infarct depolarisations. *J Cereb Blood Flow Metab* 2006; 26: 645–53.
- Strong AJ, Dreier J, Woitzik J, Bhatia R, Hashemi P, Fuhr SB, et al. Cortical-spreading depression in patients with acute subarachnoid hemorrhage. *Society for Neuroscience*. Vol. 358.7. DC: Washington; 2005.
- Veltkamp R, Sun L, Herrmann O, Wolferts G, Hagmann S, Siebing DA, et al. Oxygen therapy in permanent brain ischemia: potential and limitations. *Brain Res* 2006; 1107: 185–91.
- Watson NA, Beards SC, Altaf N, Kassner A, Jackson A. The effect of hyperoxia on cerebral blood flow: a study in healthy volunteers using magnetic resonance phase-contrast angiography. *Eur J Anaesthesiol* 2000; 17: 152–9.